

## Improving Patient Management with Strain Imaging for Right Ventricle Assessment and Monitoring

The right ventricle (RV) plays an important role in the morbidity and mortality of patients presenting with signs and symptoms of cardiopulmonary disease. Echocardiographic assessment of the right ventricle has been largely qualitative, primarily because of the difficulty with assessing RV volumes due to its unusual shape. Hence, there are minimal quantitative data on RV size and function for both normal and disease states. A shift to more quantitative measurements of RV size and function will help standardize assessment, and allow clinicians to better incorporate assessment of the right heart into an echocardiographic evaluation.

In 2010, the American Society of Echocardiography (ASE) published “Guidelines for the Echocardiographic Assessment of the Right Heart in Adults: A Report from the American Society of Echocardiography,” to assist clinicians in improving assessment and management of the RV. The guidelines recommend assessment of size and function parameters including RV and right atrium (RA) size, RV fractional area change (FAC), peak systolic annular velocity (S'), and tricuspid annular plane systolic excursion (TAPSE).

### Issue at Hand

Although echocardiographic assessment of the RV is recognized as valuable in improving patient management, there are challenges such as the RV's complex structure and physiology, inadequate analysis tools and difficulties with study interpretation.

### ASE Clinical Indications for RV Assessment

- Pulmonary embolism
- Pulmonary arterial hypertension
- Smoking
- Chronic obstructive pulmonary disease
- Cystic fibrosis
- Acute hypoxia
- Myocardial infarction or ischemia due to (proximal) right coronary artery lesion
- Repaired tetralogy of Fallot
- Repaired transposition of the great arteries
- Chronic heart failure
- Cardiac transplantation
- Arrhythmogenic right ventricular cardiomyopathy
- Hypertrophic cardiomyopathy
- Chagas disease
- Essential hypertension
- Aortic stenosis
- Aortic regurgitation
- Mitral regurgitation
- Myocardial infarction due to left anterior descending coronary artery lesion
- Diabetes mellitus
- Hypothyroidism
- Amyloidosis
- Rheumatoid arthritis
- Systemic sclerosis
- Antiphospholipid antibody syndrome
- Bechet's vasculitis
- b-thalassemia
- Renal transplantation
- Hepatopulmonary syndrome
- Normal neonates
- Aging

## Today's Challenges with Echo RV Assessment

### Structure and Physiology

- Complex shape
- Limited definition of RV due to heavy trabeculation
- Complex motion

### Analysis tools

- High inter- and intra-observer variability
- Inadequate sensitivity
- Lack of regional information
- Poor workflow, time consuming
- No tools dedicated for monitoring patients over time

### Interpretation

- Subjective
- Experience dependent
- Lack of standardization
- Typically requires 3D imaging

## About Current Standards for RV Analysis

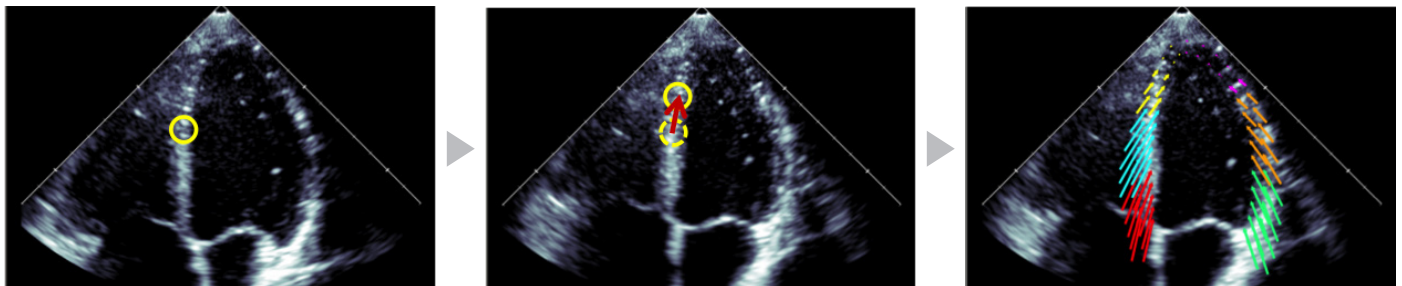
Tissue Doppler Imaging (TDI) is used to assess RV systolic motion through TAPSE and S' measurements.

### Challenges of TDI in measuring annulus motion:

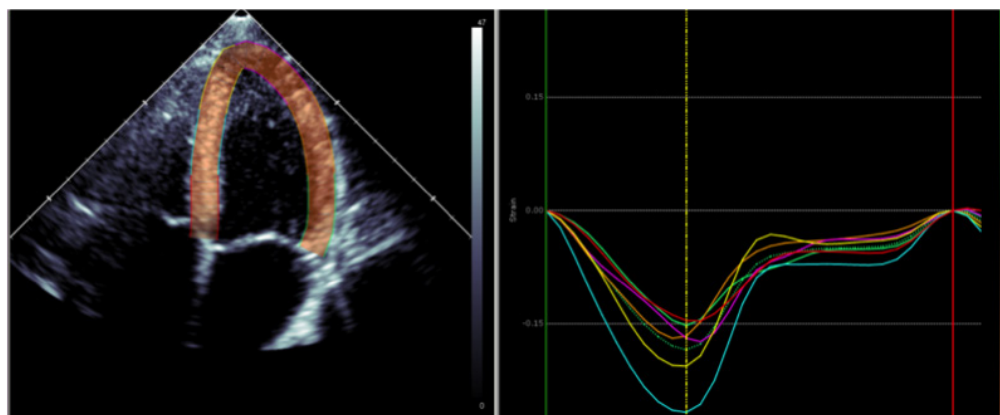
- Angle dependent and thus may not provide accurate measurement of annulus motion (it calculates the excursion towards the center of the transducer)
- Only measures motion at a fixed location regardless of what tissue passes through interrogation region
- Does not work when RV translation, probe motion or respiratory motion is present
- Peak velocity measurement can be difficult due to poor Doppler signal from spectral broadening and noise sources

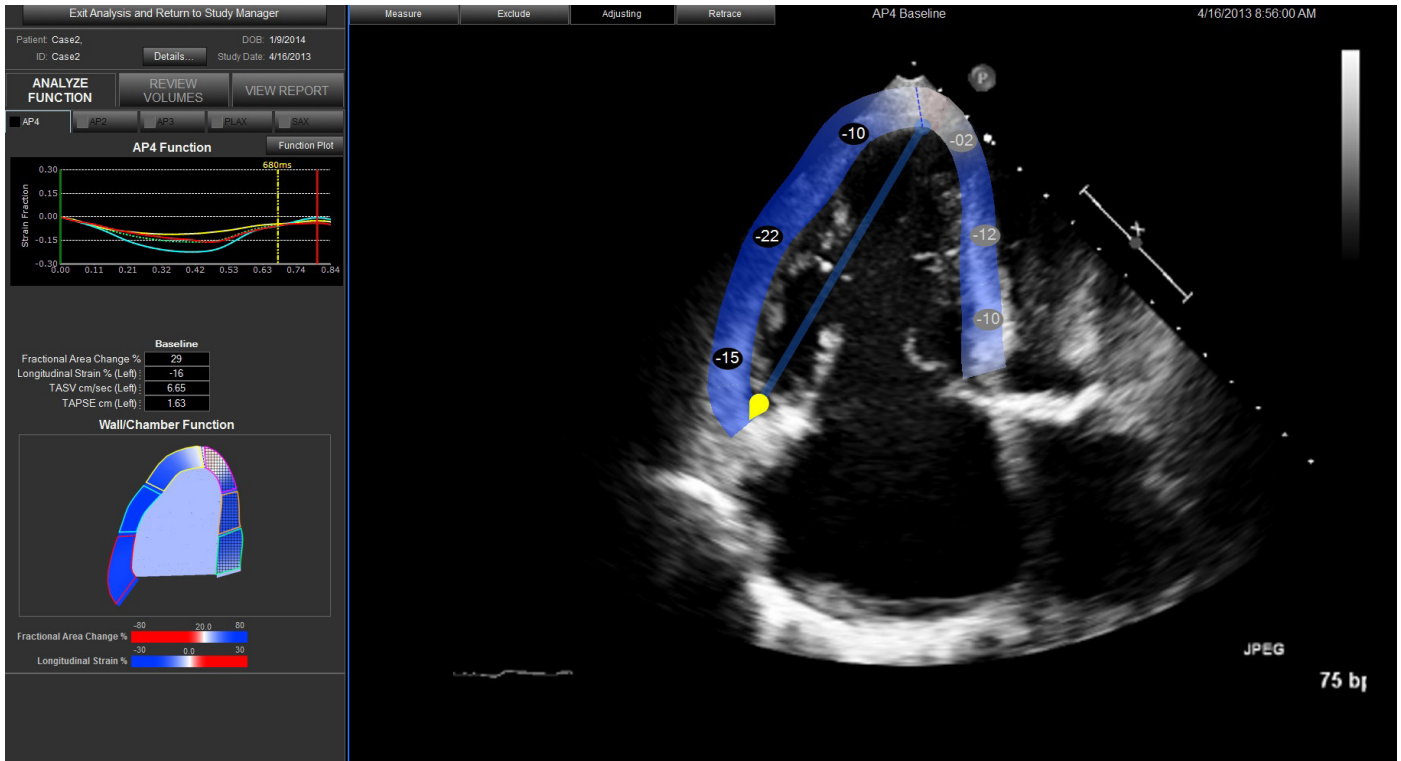
## The Solution: Speckle Tracking Strain Imaging from Epsilon Imaging

For many years, speckle tracking strain imaging has been regarded as a sensitive, quantitative tool for evaluating mechanical function of the heart. Strain imaging overcomes many of the shortcomings of TDI by providing tissue motion analysis from a 2D study that is acquisition angle independent, is not affected by tissue and probe translation, and is able to quantify motion of a specific region of tissue (e.g., annulus). Strain imaging can measure myocardium motion, contraction and relaxation, and has been shown to be clinically useful for assessment of cardiac function and health.



*Tissue motion and deformation imaging and measurements*





At American Heart Association (AHA) 2012, Roberto Lang, MD and Benjamin Freed, MD along with a team from University of Chicago Medicine presented a study “Right Ventricular Strain in Pulmonary Arterial Hypertension: Comparison Between 2D Echocardiography and Cardiovascular Magnetic Resonance.” The study analyzed 25 patients with pulmonary hypertension using both ultrasound and magnetic resonance (MR). RV longitudinal strain from ultrasound was measured using EchoInsight and RV strain from MR was measured using Diagnosoft™. The study demonstrated that results from EchoInsight were comparable to those derived from cardiac MR, suggesting that RV strain from 2D echocardiography is a reasonable and practical option for examining RV myocardial deformation.

Despite the potential clinical utility of strain imaging, there have been challenges. Traditionally, strain imaging has been research oriented and laborious to use. Additionally, the majority of strain imaging solutions require the use of a specific manufacturer’s scanner (as opposed to are “vendor

specific”), making it difficult to standardize and integrate into clinical workflow.

## Introducing EchoInsight: Visualization and Analysis for Streamlined Quality, Standardization and Workflow

EchoInsight is a validated, vendor-neutral software platform that provides visualization and analysis with practical strain imaging for streamlined workflow in the clinical environment. Developed in collaboration with cardiologists, EchoInsight aids clinicians in transforming the way they analyze and interpret echo studies.

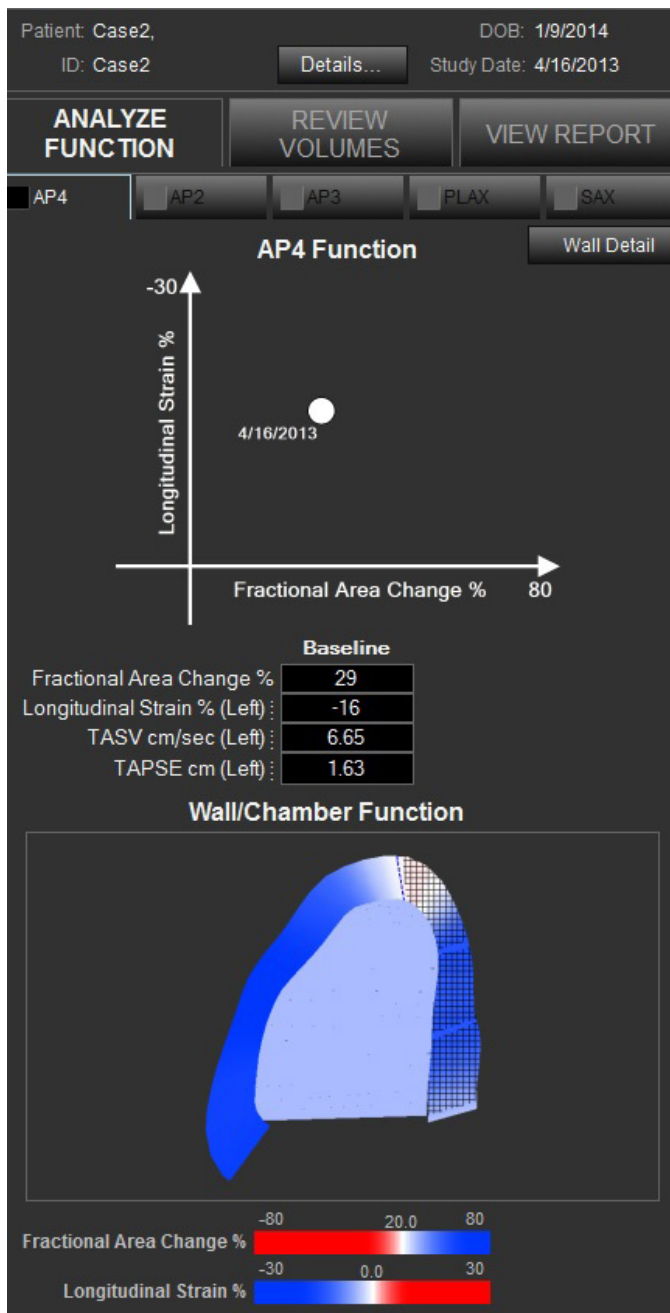
EchoInsight for Right Ventricle assists clinicians to quickly and easily integrate strain imaging into their program, and improve patient management. Features include automated processing, rapid serial study comparison, global and regional longitudinal strain and FAC trending with percent change from baseline, automated TAPSE, S’ and RV size, clear, concise, highly reliable, and detailed visual-based reporting to aid patient management and customized integration to customer healthcare IT workflow.

“This newest application from Epsilon Imaging designed specifically for RV function assessment compares well with strain analysis using cardiac MR – the gold standard,” said Benjamin Freed, MD, Northwestern Memorial Hospital. “Echolnsight for RV offers a versatile, efficient and economic approach to thoroughly assess RV and improve management of patients when evaluating the right heart for a variety of indications.”

### TAPSE and S' with Echolnsight

Measuring annulus motion using Epsilon speckle tracking techniques overcomes the challenges of traditional, Doppler based methods. Echolnsight will track specified tissue regions like the tricuspid annulus throughout the cardiac cycle, as opposed to a fixed location like TDI. In addition, the velocity and excursion of the annulus is calculated with respect to the RV apex, avoiding errors associated with probe motion and RV translation.

“Echolnsight for RV offers quick and reliable visualization and analysis with practical strain imaging for function assessment and comparison over time,” said Roberto Lang, MD, University of Chicago Medicine. “RV is challenging to assess in 2D imaging, Echolnsight for RV brings robust and intuitive tissue motion analysis along with automated cardiac function measurements to clinical practice. This added quantitative data in a practical solution can assist clinicians by improving confidence in interpretation when evaluating RV.”



**Epsilon Imaging, Inc.** tel: 734.369.5100  
 3917 Research Park Drive, Suite B7 fax: 734.369.5120  
 Ann Arbor, Michigan 48108 USA email: info@epsilon-imaging.com

Learn more about integrating Echolnsight for RV into your practice: [www.epsilon-imaging.com](http://www.epsilon-imaging.com).